

Efficacy of Infrazygomatic Approach Combined with Anterior Middle Superior Alveolar Nerve Block versus Standard Technique for Scaling and Root Planing: A Randomised Clinical Trial

AROCKIA ANTONY PRAVEEN¹, VENKADASSALAPATHY SANTHOSH², DHAYANAND JOHN VICTOR³, RATHINASAMY KADHIRESAN⁴, C VIKRAM⁵, SHERYL DOLLY⁶, L VISHALATCHI⁷



ABSTRACT

Introduction: A profound anaesthetic technique is essential for performing periodontal procedures with an effective onset and adequate duration of action. The infrazygomatic approach combined with the Anterior Middle Superior Alveolar (AMSA) nerve block may serve as a better alternative to the conventional AMSA technique alone in the maxillary region, as it helps minimise palatal mucosal blanching and improves the extent of anaesthesia. The present study was conducted to evaluate whether the addition of the infrazygomatic approach enhances anaesthetic efficacy, reduces intraoperative discomfort, and shortens surgical duration during non surgical periodontal therapy compared to the AMSA technique alone.

Aim: To assess the efficacy of anaesthesia in the maxilla by giving AMSA and an infrazygomatic approach, along with AMSA injections with 2% lidocaine and 1:80000 adrenalin anaesthetic solution.

Materials and Methods: A randomised, single-blinded, parallel-arm clinical trial was conducted in the Department of Periodontics, SRM Dental College, Ramapuram, Chennai, Tamil Nadu, India, from August 2021 to October 2021, to evaluate the efficacy of two different anaesthetic techniques in terms of pain intensity and duration of surgery. A total of 80 patients meeting the primary inclusion criteria {age 18–70 years, American Society of Anaesthesiologists (ASA) physical status I and II } were selected and randomly allocated using allocation concealment into two groups- Control group and Test group consisting of 40 patients each. The outcome assessor was blinded to the group allocation. The procedures

were performed following a standardised protocol, and pain intensity and duration of surgery were recorded. Demographic parameters such as age and gender were documented. Statistical analysis was carried out using Statistical Package for Social Sciences (SPSS) software version 26.0, (Armonk, NY: IBM Corp., 2019). Descriptive statistics were used to calculate mean and standard deviation, and inferential analysis was performed using the Mann–Whitney U test. A p-value <0.05 was considered statistically significant.

Results: Eighty participants were included in the analysis with equal gender distribution in both groups (24 males and 16 females in each group). The mean age was 35.93±6.05 years in the test group and 41.95±7.67 years in the control group. The test group demonstrated significantly lower pain scores compared to the control group, with mean Visual Analogue Scale (VAS) scores of 0.65±0.74 versus 3.88±1.80 (Z=7.14; p<0.01) and Wong–Baker FACES® pain scores of 0.60±0.93 versus 3.50±1.91 (Z=6.61; p<0.01). The mean duration of surgery was also significantly shorter in the test group (59.0±6.71 minutes) compared to the control group (83.62±8.69 minutes; p<0.01). Intergroup comparisons using the Mann–Whitney U test revealed highly statistically significant differences favouring the infrazygomatic approach combined with AMSA anaesthesia.

Conclusion: The infrazygomatic approach with AMSA was found to be an effective method in order to provide good patient compliance. It was also found to be effective in reducing intraoperative pain perception compared to the standard AMSA technique. Hence, this technique can be considered as a beneficial adjunct during non surgical periodontal therapy.

Keywords: Anaesthesia, Injection, Visual analogue scale

INTRODUCTION

Traditionally, infiltration anaesthesia was commonly used to anaesthetise the maxillary anterior region; however, the disadvantages of multiple needle insertions, increased patient discomfort, prolonged chairside time, and reduced patient compliance prompted the search for alternative techniques. This led to the introduction of the Anterior Middle Superior Alveolar (AMSA) nerve block, which was discovered by Friedman and Hochman in 1998 [1]. The rationale behind the AMSA technique is to provide wide-field maxillary anaesthesia through a single palatal injection, thereby minimising the number of injections required and improving patient acceptance.

This technique holds a great advantage of anaesthetising the maxilla up to the premolar region without causing lip numbness and without discomfort to the facial muscles [2]. The absence of upper lip and facial muscle anaesthesia is a significant clinical advantage, particularly during periodontal procedures, as it allows better patient comfort, normal facial expression, and accurate assessment of occlusion and phonetics during treatment. The questionable pulpal anaesthesia reported by Fukayama H et al., [3] and Lee S et al., [4] may be attributed to limited diffusion of the anaesthetic solution through the palatal bone, anatomical variations in bone thickness, and incomplete blockade of segmental maxillary nerve branches, despite achieving excellent palatal soft tissue haemostasis. This

highlights the need for modification or supplementation of the AMSA technique to ensure complete pulpal anaesthesia throughout the maxillary quadrant.

Pain is a subjective experience caused by the interaction of physiological and psychosocial factors [5]. In the AMSA nerve block technique, anaesthesia is administered at the subneural plexus formed by overlapping branches of the anterior and middle superior alveolar nerves [6]. Pain is one of the most frequently encountered symptoms in dentistry and is a major source of distress for both the dentist and the patient [7]. Therefore, any technique that reduces the number of injections while ensuring profound anaesthesia becomes clinically essential, especially in periodontal therapy, where extensive soft and hard tissue manipulation is required.

The ability to deliver safe and effective local anaesthesia is a vitally important skill for all dental professionals. Maxillary non surgical periodontal therapy, involving Scaling and Root Planing (SRP) of diseased periodontal tissues, often requires up to five injections to achieve adequate quadrant anaesthesia. Posterior superior alveolar, middle superior alveolar, and anterior superior alveolar nerve blocks are required to anaesthetise the buccal tissues, along with greater palatine and nasopalatine nerve blocks for palatal anaesthesia. The middle superior alveolar nerve supplies sensory innervation to the maxillary premolars and the mesiobuccal root of the first maxillary molar, while the anterior superior alveolar nerve supplies pulpal innervation to the central incisors, lateral incisors, and canines [8].

The AMSA injection is well-delineated in its ability to deliver anaesthesia to the maxillary incisors, canines, premolars, and their associated periodontal tissues. Its major advantage lies in reducing the total volume of anaesthetic solution, minimising multiple needle penetrations, providing superior haemostasis, and enhancing patient comfort during lengthy periodontal procedures. However, several studies have reported inconsistent pulpal anaesthesia with AMSA, particularly in the second molar region and occasionally in central incisors, which has been attributed to variations in palatal bone thickness, diffusion limitations, and segmental maxillary nerve anatomy [1-4]. The AMSA injection is administered via the palatal approach, and due to limited diffusion to the posterior maxilla along with variable palatal bone thickness, molar pulpal anaesthesia may be inadequate. Therefore, this limitation necessitates the incorporation of an adjunct infrazygomatic approach to achieve complete maxillary quadrant anaesthesia.

Therefore, in the present technique, an additional anaesthetic delivery through the infrazygomatic approach is employed along with the AMSA injection. The necessity of combining these two techniques lies in achieving comprehensive pulpal and periodontal anaesthesia of the entire maxillary quadrant with only two injections, thereby significantly reducing patient discomfort, anxiety, and treatment time. This combined approach ensures that the entire maxilla within a quadrant is effectively anaesthetised, making it especially advantageous for maxillary non surgical periodontal therapy.

Yadav AK et al., evaluated the efficacy of pain reduction using the AMSA technique and the infraorbital technique and reported that the AMSA technique was superior in reducing pain perception [9]. However, literature lacks evidence comparing AMSA alone with a combined infrazygomatic and AMSA approach in terms of overall anaesthetic efficacy across a full maxillary quadrant. Therefore, based on the existing literature gap, the present study was undertaken to assess the efficacy and clinical advantage of achieving maxillary quadrant anaesthesia using a combination of AMSA and infrazygomatic approaches with 2% lidocaine and 1:80,000 adrenaline, aiming to reduce the number of injections while providing profound and predictable anaesthesia.

The null hypothesis stated that there is no statistically significant difference in the efficacy of anaesthesia between AMSA alone and the combined AMSA with infrazygomatic approach in maxillary non-surgical periodontal therapy.

The alternate hypothesis states that there is a statistically significant difference in the efficacy of anaesthesia between AMSA alone and the combined AMSA with infrazygomatic approach in maxillary non surgical periodontal therapy.

MATERIALS AND METHODS

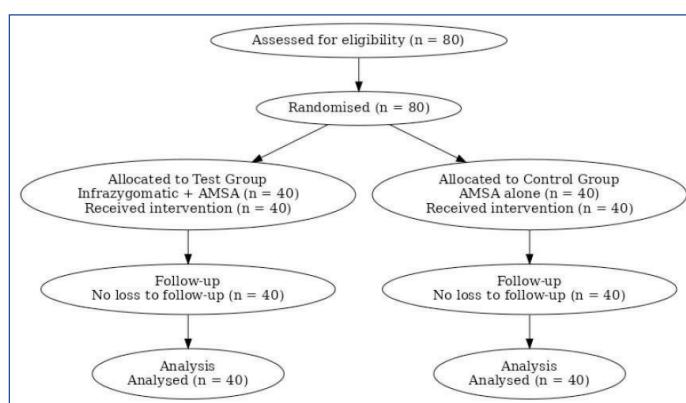
This randomised, single-blinded, parallel-arm clinical trial was conducted among patients reporting to the Department of Periodontics, SRM Dental College, Ramapuram, Chennai, Tamil Nadu, India, over a period of three months, from August 2021 to October 2021. Ethical clearance was obtained from the Institutional Review Board [SRMU/M&HS/SRMDC/2019/PG/010] before the commencement of the study and registered in CTRI trial [REF/2019/11/029340].

Sample size calculation: Sample size estimation was performed using G*Power software (version 3.1.9.2) based on the comparison of two independent proportions. The calculation was derived from previously published data by Yadav AK et al., [9], where the lowest pulpal anaesthetic success rate was 42% for the AMSA nerve block and 11% for the infraorbital nerve block. With a confidence level of 95% and a statistical power of 80%, the minimum required sample size was calculated as 62 participants. To account for potential dropouts, a total of 80 participants were enrolled, with 40 participants in each group.

Inclusion criteria: Patients aged between 18 and 70 years, patients presenting with periodontal pockets ≥ 5 mm, patients undergoing maxillary non surgical periodontal therapy like SRP under local anaesthesia, and patients classified under American Society of Anaesthesiologists (ASA) physical status I and II were included [10].

Exclusion criteria: Patients on analgesic, anti-inflammatory, or antidepressant medications; patients with known allergy to local anaesthetic agents; pregnant and lactating women; patients with bleeding disorders or neurological disorders; and patients with missing maxillary premolars were excluded.

Allocation concealment and randomisation: Randomisation was performed using the opaque sealed envelope method. Eighty opaque sealed envelopes containing random numbers from 1 to 80 were prepared. Participants selecting numbers from 1–40 were allocated to the test group, while those selecting numbers from 41–80 were allocated to the control group. A simple random sampling technique was employed. Only patients fulfilling the inclusion and exclusion criteria and providing written informed consent were included in the study. A simple random sampling technique was employed for participant selection, shown in Consolidated Standards of Reporting Trials (CONSORT) [Table/Fig-1].



[Table/Fig-1]: CONSORT diagram of the study (flowchart).

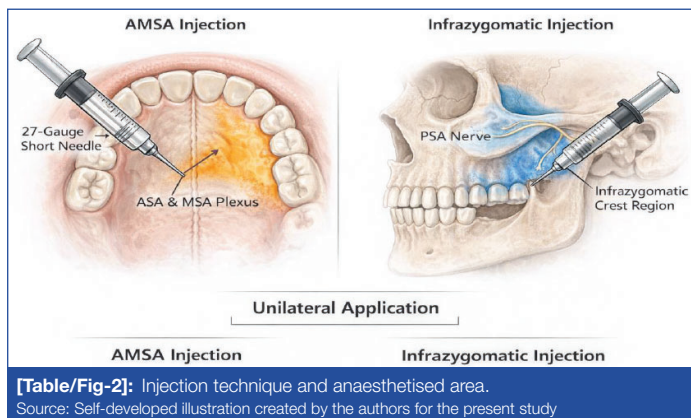
Source: Self-developed illustration created by the authors for this study

Study Procedure

A total of 80 patients meeting the primary inclusion criteria were selected and randomly allocated using allocation concealment into two groups-

- Control group (n=40) - received the Anterior Middle Superior Alveolar (AMSA) nerve block alone using lidocaine, and
- Test group (n=40) - received a combination of AMSA nerve block and Infrazygomatic Approach (IZA) using lidocaine.

The test group received 2 mL of 2% lidocaine with 1:80,000 adrenaline administered via AMSA and infrazygomatic approaches, while the control group received the same dose of local anaesthetic through AMSA injection alone [Table/Fig-2]. All clinical procedures were performed by a single operator, and the assessment of clinical parameters was carried out by a blinded examiner. Due to the nature of the intervention, the operator could not be blinded; therefore, the study was conducted as a single-blinded randomised clinical trial, with the outcome assessor and participants blinded to group allocation.



The AMSA injection was administered via the palatal approach using a 27-gauge short needle. The injection site was identified midway between the maxillary first and second premolars, halfway between the free gingival margin and the mid-palatal suture. Following topical anaesthetic application, the needle was inserted perpendicular to the palatal surface until gentle bony resistance was encountered, and the anaesthetic solution was deposited slowly over 2–3 minutes to facilitate diffusion through the cancellous palatal bone. This targeted the subneural dental plexus formed by the convergence of the anterior and middle superior alveolar nerves.

The AMSA technique was intended to anaesthetise the maxillary central incisors, lateral incisors, canines, premolars, and their associated buccal and palatal periodontal tissues within the treated quadrant. No separate palatal injection was administered, as palatal soft tissue anaesthesia was achieved through the AMSA injection itself. As AMSA alone may provide inadequate anaesthesia in the posterior maxilla due to variable palatal bone thickness and posterior superior alveolar nerve supply, an adjunct infrazygomatic approach was incorporated in the test group. The infrazygomatic injection was administered extra-orally at the infrazygomatic crest region, targeting the posterior superior alveolar nerve to achieve reliable pulpal and periodontal anaesthesia of the maxillary molars and posterior alveolar bone, thereby compensating for the limited posterior diffusion and inconsistent pulpal anaesthesia associated with AMSA alone.

The combined AMSA and infrazygomatic approach ensured complete anaesthesia of the entire maxillary quadrant, including anterior teeth, premolars, molars, and their associated periodontal tissues, while reducing the need for multiple conventional injections.

Outcomes: The primary outcome measure was pain perception during the procedure, and the secondary outcome measure was the duration of the non surgical periodontal therapy. Pain perception was assessed using the Visual Analogue Scale (VAS) [11] and the Wong–Baker FACES[®] pain scores [12]. VAS scores ranged from 0 to 10, where 0 indicated “no pain” and 10 indicated

“worst imaginable pain.” The Faces Pain Rating Scale consisted of six facial expressions scored from 0 (no pain) to 5 (severe pain). Pain scores were recorded immediately after completion of the procedure.

Two pain assessment scales were employed to enhance the reliability and validity of pain evaluation, as VAS provides a quantitative continuous measure of pain intensity, while the Faces Pain Rating Scale offers a simplified visual assessment that improves patient understanding and reduces subjective bias. The duration of the procedure was recorded in minutes to compare treatment time between groups. Demographic parameters such as age and gender were recorded for all participants. No intraoperative or postoperative complications such as haematoma, prolonged numbness, allergic reactions, or soft tissue injury were observed in either group; hence, no additional management was required. Prior to the start of the study, examiner calibration was performed. All clinical assessments were carried out by a single calibrated examiner. Intra-examiner reliability was assessed by repeating pain score recordings in 10 randomly selected participants, and agreement was evaluated using the Intraclass Correlation Coefficient (ICC), which showed good reliability (ICC > 0.80).

STATISTICAL ANALYSIS

Data analysis was performed using SPSS software (IBM SPSS Statistics for Windows, version 26.0, Armonk, NY: IBM Corp., 2019). Normality of data was assessed using Kolmogorov–Smirnov and Shapiro–Wilk tests. As the data did not follow a normal distribution, non parametric tests were applied. Descriptive statistics were used to calculate mean values, and the Mann–Whitney U test was used to analyse differences between the test and control groups. The level of statistical significance was set at 5% ($\alpha=0.05$), and a p-value <0.05 was considered statistically significant.

RESULTS

Demographic Details

The mean age of participants in the test group was 35.93±6.05 years, while the mean age in the control group was 41.95±7.67 years. The test group comprised 24 male and 16 female participants, and the control group comprised 24 male and 16 female participants [Table/Fig-3].

Demographic variables	Test group	Control group	p-value
Age (in years) (Mean±SD)	35.93±6.05	41.95±7.67	0.062
Gender n (%)			
Male	24 (60%)	24 (60%)	1.00
Female	16 (40%)	16 (40%)	

[Table/Fig-3]: Demographic characteristics of the study groups (N=80). Age comparison was performed using the Mann–Whitney U test (p-value=822), and gender distribution was compared using the Chi-square test (χ^2 value=0). A p-value≤0.05 was considered statistically significant

Clinical observations : No adverse effects or complications were observed in any patient. Comparison of the mean rank difference of the VAS score among the study groups. The median pain score was significantly higher in the control group (3.88) than in the test group (0.65) [Table/Fig-4]. Comparison of the mean rank difference of the face score among the study groups. The mean was found to be higher in the control group (3.50) than in the test group (0.60) [Table/Fig-5]. Mean difference in the duration of surgery among the study groups was found to be higher in the control group (83.62±8.69 minutes) compared to the test group (59.0±6.71 minutes) [Table/Fig-6].

DISCUSSION

The present study aimed to evaluate whether a combined AMSA and infrazygomatic approach could provide superior maxillary

Groups	Mean±SD	Mean rank	Sum of ranks	Z-score	p-value
Test group	0.65±0.74	22.25	890.00	7.14	<0.01
Control group	3.88±1.80	58.75	2350.00		

[Table/Fig-4]: Comparison of mean rank difference of VAS score among the study groups.

Statistical test applied: Mann-Whitney U test; p-value<0.05 considered statistically significant; VAS: Visual analogue scale; SD: Standard deviation

Group	Mean±SD	Mean rank	Sum of ranks	Z-score	p-value
Test group	0.60±0.93	24.20	968.00	6.61	<0.01
Control group	3.50±1.91	56.80	2272.00		

[Table/Fig-5]: Comparison of the mean rank difference of face scores among the study groups.

Statistical test applied: Mann-Whitney U test; p-value <0.05 considered statistically significant; SD: Standard deviation

Variables	Test group	Control group
Mean	59.00	83.62
Std. error of mean	1.06	1.37
Std. Deviation	6.71	8.69
Variance	45.12	75.62
Range	25.00	35.00
Minimum	45.00	65.00
Maximum	70.00	100.00
p-value	<0.01*	

[Table/Fig-6]: Mean difference on duration of surgery among the study groups in minutes.

Duration of surgery was measured in minutes. Intergroup comparison was performed using the Mann-Whitney U test. Z=7.14, p<0.01, indicating a highly statistically significant difference. p<0.05 is considered statistically significant

quadrant anaesthesia with reduced pain perception compared to AMSA alone during non surgical periodontal therapy. The findings demonstrated significantly lower pain scores and reduced surgical duration in the test group, indicating enhanced anaesthetic efficacy of the combined approach.

Local anaesthesia remains the cornerstone of dental practice, enabling painless execution of diagnostic and therapeutic procedures. Advancements in anaesthetic techniques have primarily focused on improving patient comfort, reducing the number of injections, and ensuring profound pulpal and periodontal anaesthesia [13,14]. Alam MN et al., emphasised that effective diffusion of local anaesthetic solutions into surrounding tissues plays a crucial role in minimising pain perception, which supports the rationale for adopting techniques that enhance anaesthetic spread [15].

Conventional maxillary anaesthetic techniques, including infiltration and anterior superior alveolar nerve blocks, often require multiple injections to achieve quadrant-level anaesthesia, thereby increasing patient discomfort and chairside time [16,17]. In contrast, the AMSA technique was introduced to provide wide-field anaesthesia through a single palatal injection. However, previous studies have reported inconsistent pulpal anaesthesia with AMSA alone, particularly in the posterior maxillary region, due to anatomical variations in palatal bone thickness and nerve distribution [3,4].

The significantly lower VAS and Faces Pain Rating Scale scores observed in the test group suggest that supplementing AMSA with an infrazygomatic approach enhances anaesthetic depth while reducing pain associated with injection and instrumentation. These findings align with Cetkovic D et al., [18], who reported improved patient comfort with advanced maxillary nerve block techniques compared to conventional methods. Similarly, De Tolentino SL et al., demonstrated that AMSA provides effective anaesthesia in the anterior maxilla, supporting its selection as the control technique in the present study [19].

Gender-based equal distribution was incorporated, as pain perception is known to vary with gender and age, a phenomenon well-described by Defrin R et al., [20]. By accounting for this variable, the present study minimised potential bias related to pain reporting. The use of two pain assessment tools—VAS and Faces Pain Rating Scale - allowed comprehensive evaluation of subjective pain perception across participants with varying cognitive and emotional responses to pain.

The duration of anaesthesia observed with AMSA alone, lasting up to 89 minutes, was consistent with previous studies reporting that AMSA anaesthesia provides an expected duration ranging from 45 to 90 minutes, as cited by Acharya AB et al., [13]. Palatal blanching, a commonly reported transient effect of palatal injections, was minimal and restricted to the mid-palatal raphe, suggesting adequate yet controlled vasoconstriction without adverse sequelae [14].

Clinically, the combined AMSA and infrazygomatic approach offers a significant advantage by achieving complete maxillary quadrant anaesthesia with only two injections, eliminating the need for multiple buccal and palatal infiltrations. This technique may be particularly beneficial during extensive non surgical periodontal therapy, as it improves patient comfort, reduces treatment time, and enhances operator efficiency.

Based on the statistically significant differences observed between the test and control groups, the null hypothesis was rejected, and the alternate hypothesis was accepted, confirming that the combined AMSA with infrazygomatic approach provides superior anaesthetic efficacy compared to AMSA alone.

Future studies with larger sample sizes, objective pain biomarkers, and evaluation of patient anxiety levels are recommended to further validate the clinical superiority of this combined approach. Additionally, comparative studies assessing different local anaesthetic agents and concentrations may provide further insights into optimising maxillary anaesthesia protocols.

Limitation(s)

The primary limitation of the study is the subjective assessment of pain using VAS and Faces Pain Rating Scale, which may be influenced by individual pain perception and anxiety levels. Anatomical variations in maxillary bone thickness and nerve distribution, as well as patient-related factors such as pain threshold and previous dental experiences, were not objectively assessed and may have acted as confounding factors. Although the sample size was statistically calculated and adequately powered, the single-centre design of the study may limit the generalisability of the findings to broader populations. Multicentric studies with diverse patient populations are recommended to validate the results. Additionally, pulpal anaesthesia was not objectively verified using vitality tests, and only one local anaesthetic formulation was evaluated.

CONCLUSION(S)

In contemporary clinical practice, emerging technologies that reduce operator workload and enhance patient compliance are highly valued. The combined infrazygomatic and AMSA local anaesthesia technique is more effective in pain control and in reducing surgical time when compared with the conventional AMSA technique alone. Therefore, the infrazygomatic approach may be considered a valuable adjunct for clinicians in achieving improved pain control during maxillary periodontal procedures.

REFERENCES

- [1] Friedman MJ, Hochman MN. The AMSA injection: A new concept for local anesthesia of maxillary teeth using a computer-controlled injection system. *Quintessence Int.* 1998;29(5):297-303.
- [2] Chourasia NR, Vastani A, Pahlajani V, Shrivastav A, Choubey S, Vajpayee S, et al. Effectiveness of anterior and middle superior alveolar nerve block for anaesthesia of maxillary teeth using a conventional syringe: A randomised prospective study. *J Maxillofac Oral Surg.* 2022;21(2):616-19. Doi: 10.1007/s12663-020-01432-w.

- [3] Fukayama H, Yoshikawa F, Kohase H, Umino M, Suzuki N. Efficacy of anterior and middle superior alveolar (AMSA) anaesthesia using a new injection system: The Wand. *Quintessence Int.* 2003;34(7):537-41.
- [4] Lee S, Reader A, Nusstein J, Beck M, Weaver J. Anaesthetic efficacy of the anterior middle superior alveolar (AMSA) injection. *Anesth Prog.* 2004;51(3):80-89.
- [5] McKillop HN, Banez GA. A broad consideration of risk factors in pediatric chronic pain. *J Dent.* 2016;3(4):38-47.
- [6] Malamed SF. *Handbook of Local Anaesthesia.* 6th ed. St. Louis: Mosby Elsevier; 2013
- [7] Emodi-Perlman A, Yoffe T, Rosenberg N, Eli I, Alter Z, Winocur E. Prevalence of psychologic, dental, and temporomandibular signs and symptoms among chronic eating disorder patients: A comparative control study. *J Orofac Pain.* 2008;22(3):147-58.
- [8] Mittal M, Kumar A, Srivastava D, Sharma P, Sharma S. Pain perception: Computerised versus traditional local anaesthesia in pediatric patients. *J Clin Pediatr Dent.* 2015;39(5):470-74.
- [9] Yadav AK, Singh A, Pradhan L, Jaisani MR, Dongol A, Acharya P, et al. Comparison of anterior middle superior alveolar nerve block and infraorbital nerve block for maxillary anterior teeth anesthesia: A randomized clinical trial. *J Oral Maxillofac Surg Med Pathol.* 2018;30(3):233-37.
- [10] Hendrix JM, Garmon EH. *American Society of Anesthesiologists Physical Status Classification System.* StatPearls [Internet]. Treasure Island (FL): StatPearls Publishing; 2023.
- [11] McCormack HM, Horne DJ, Sheather S. Clinical applications of visual analogue scales: A critical review. *Psychol Med.* 1988;18(4):1007-19.
- [12] Wong DL, Baker CM. Pain in children: Comparison of assessment scales. *Pediatr Nurs.* 1988;14(1):09-17.
- [13] Acharya AB, Banakar C, Rodrigues SV, Nagpal S, Bhadbhade S, Thakur SL. Anterior middle superior alveolar injection is effective in providing anaesthesia extending to the last standing molar in maxillary periodontal surgery. *J Periodontol.* 2010;81(8):1174-79.
- [14] Loomer PM, Perry DA. Computer-controlled delivery versus syringe delivery of local anaesthetic injections for therapeutic scaling and root planing. *J Am Dent Assoc.* 2004;135(3):358-65.
- [15] Alam MN, Chandrasekharan SC, Mohan V, Anitha B. AMSA (anterior middle superior alveolar) injection: A boon to maxillary periodontal surgery. *J Clin Diagn Res.* 2011;5(3):675-78.
- [16] Velasco I, Soto R. Anterior and middle superior alveolar nerve block for anaesthesia of maxillary teeth using a conventional syringe. *Dent Res J (Isfahan).* 2012;9(5):535-40.
- [17] Corbett IP, Jaber AA, Whitworth JM, Meechan JG. A comparison of the anterior middle superior alveolar nerve block and infraorbital nerve block for anaesthesia of maxillary anterior teeth. *J Am Dent Assoc.* 2010;141(12):1442-48.
- [18] Cetkovic D, Antic S, Antonijevic D, Brkovic BM, Djukic K, Vujaskovic G, et al. Nutrient canals and porosity of the bony palate: A basis for the biological plausibility of the anterior middle superior alveolar nerve block. *J Am Dent Assoc.* 2018;149(10):859-68.
- [19] De Souza Tolentino L, Barbisan Souza A, Girardi AA, Romito GA, Araújo MG. The anaesthetic effect of the anterior middle superior alveolar technique (AMSA). *Anesth Prog.* 2015;62(4):153-58.
- [20] Defrin R, Eli I, Pud D. Interactions among sex, ethnicity, religion, and gender role expectations of pain. *Genet Med.* 2011;8(3):172-83.

PARTICULARS OF CONTRIBUTORS:

1. Senior Lecturer, Department of Periodontics, Sri Venkateswara Dental College and Hospital, Chennai, Tamil Nadu, India.
2. Professor, Department of Periodontics, SRM Dental College, Chennai, Tamil Nadu, India.
3. Professor and Head, Department of Periodontics, SRM Dental College, Chennai, Tamil Nadu, India.
4. Professor, Department of Periodontics, Sri Venkateswara Dental College and Hospital, Chennai, Tamil Nadu, India.
5. Senior Lecturer, Department of Periodontics, Sri Venkateswara Dental College and Hospital, Chennai, Tamil Nadu, India.
6. Assistant Professor, Department of Periodontics, Priyadarshini Dental College and Hospital, Chennai, Tamil Nadu, India.
7. Postgraduate Student, Department of Periodontics, Sri Venkateswara Dental College and Hospital, Chennai, Tamil Nadu, India.

NAME, ADDRESS, E-MAIL ID OF THE CORRESPONDING AUTHOR:

Dr. Arockia Antony Praveen,
Senior Lecturer, Department of Periodontics, Sri Venkateswara Dental College and Hospital, Chennai-600130, Tamil Nadu, India.
E-mail: antonypraveen911@gmail.com

PLAGIARISM CHECKING METHODS: [Jain H et al.]

- Plagiarism X-checker: Apr 14, 2025
- Manual Googling: May 01, 2026
- iThenticate Software: May 03, 2026 (1%)

ETYMOLOGY: Author Origin

EMENDATIONS: 8

AUTHOR DECLARATION:

- Financial or Other Competing Interests: None
- Was Ethics Committee Approval obtained for this study? Yes
- Was informed consent obtained from the subjects involved in the study? Yes
- For any images presented appropriate consent has been obtained from the subjects. No

Date of Submission: **Mar 22, 2025**

Date of Peer Review: **Jun 26, 2025**

Date of Acceptance: **May 05, 2026**

Date of Publishing: **Jul 01, 2026**